

THE PORTERS OF UR

Theya Molleson & Dawn Hodgson
The Natural History Museum, London

ABSTRACT

A reappraisal of skeletal remains from Ur excavated in the last century has revealed some exceptional morphologies of shape robusticity or muscle development. It is proposed that these changes result from intensive performance of restricted activities from early age, since it is mainly whilst the skeleton is still growing that the bones can be so modeled by forces imposed upon them. From an analysis of the bone can be so modeled by activities are suggested. The existence of contemporary illustration made this much more rewarding. It seems that many had carried great loads by various means, during their lives. The presence of such tasks in a population implies a role specialization that amounts to child labour, even slavery.

KEY-WORDS

Royal cemetery, Ur, Al-'Ubaid, skeletons, activity related morphology, porters, head-load, back-pack, Sambul porter, Standard of Ur.

1. INTRODUCTION

Sir Leonard Woolley excavated at Ur and Al-'Ubaid between 1922 and 1934. Human remains were found at all levels dating from 4000BC to 600BC. A selection of the bones was sent back to London for further study by Sir Arthur Keith at the Royal College of Surgeons, London. Keith described some of the material from both Al-'Ubaid and Ur but there is additional material which has not previously been published. The human material was transferred to the Natural History Museum in 1950 and 1963. We have looked again at all the skeletons that are still available, compared them with the written record and tried to add a further dimension to the work already done by Keith who was primarily interested in the racial origins of the people who lived at Ur.

2. PREVIOUS STUDY OF THE REMAINS FROM UR

Although skeletal material was found at the earlier levels none survives dating to before the time of the Royal Cemetery which was in use from the Early Dynastic up to the Sargonic period, about 1000 years. Ur had become a well-developed city-state by the Early Dynastic period. The dead were buried in cemeteries outside the Temple complexes. Woolley divided the cemetery chronologically into four main periods chiefly by the artefacts found in the tombs.

- I. Early and Predynastic cemetery. Two phases A and B, with phase A including all the Royal tombs and 389 of the rest, and phase B comprising 271 graves.
- II. Graves with bodies partially cremated belonging to the 1st Dynasty.
- III. 15 graves of the 2nd Dynasty.
- IV. 408 graves from the Sargonic cemetery.

The Royal tombs are dated to about 2450-2300 BC and were very much richer than any of the others (Reade 2000, 91); however, they had usually been robbed in antiquity. The richness of the furnishings in the unrobbed tombs and the ritual killing of the attendants have all been described in great detail (Woolley 1934, Woolley and Moorey 1982). Many of the skeletal remains in the collection come from the Royal Cemetery. There are three Royal tombs represented:

- PG755 Meskalamdug,
- PG800 Pu-abi (Shubad),
- The four attendants of a minor royal PG1648,
- A private burial PG1573.

All of these come from the early levels, IA, in Woolley's classification, and were described by Arthur Keith.

In addition there are three other individuals from IB:

- PG211 an old adult, possibly female,
- PG1559 a five and a half month fetus,
- PG1651 a child, ten to twelve years old.

The First Dynasty of Ur followed the Early Dynastic period. This was a continuation of the early dynastic settlement, since the new Temple surrounded and enclosed the earlier one. The cemetery was still used but no representative of this period survives; and the only one from the Second Dynasty comes from the cemetery at Al-'Ubaid, some four miles (6.25kms) from Ur. It is numbered C18 (AK8) and derives from a very late grave.

The grave PG1483 probably comes from the Sargonid (Akkadian) cemetery, used after Sargon's conquest of Ur and his successors from 2200-2145BC, although it has Larsa type pots (Woolley 1934, 506).

The Third Dynasty was a period of great building; Ur Nammu rebuilt the ziggurat in the Temple complex; but the city was finally overthrown and the kings of Isin and Larsa, once vassal states, became the new rulers and rebuilt the city. Woolley excavated the residential area in detail. He mapped the streets and houses, and was able to produce a city plan. Large houses lined narrow lanes; each looked inward to a courtyard into which all rooms opened. The houses, according to Woolley, were two stories in height, with a wooden gallery on the upper floor to provide access to the rooms. In contrast to the earlier period, in which the dead were buried in cemeteries, most of the houses had private chapels and some had brick vaulted tombs used for the burial of the dead of the family. Sometimes single burials occurred below the floors of the rooms. This was interpreted as indicating a new population with different burial practices (Woolley 1934,42).

The fragmented remains of seven individuals from the Larsa period survive:

- G43 AHa & b: 2 skulls,
- LG45 and LG46 (formerly numbered G212 and G213) two skulls,
- G48 AH, an elderly female,
- Larsa 1 unnumbered skull,
- G154 AH, mature female.

There is one skeleton, 32G31, from the Neo-Babylonian period, 600-300BC. At this time Ur was not so densely populated. The houses were further apart, but burials - in oval terra-cotta coffins - continued below the rooms of the houses.

3. NEW STUDIES OF THE HUMAN REMAINS

The remains of 24 individuals are available for examination in the Natural History Museum, London. Where we have identified more than one individual under a given number we have lettered them alphabetically. All the bones, many still wrapped in the newspapers of the time as they were originally packed, were identified if possible with the records of both Woolley and Keith. They were then looked at in detail to confirm the work done by Keith.

It was noted that several of the skeletons had very marked muscle attachments and it was suggested that these might offer clues as to the activities of the individuals during their lifetime. The muscles, which had been used so extensively, were noted and the activities, which might have led to such a change assessed. These activities were then compared with those which were known to have taken place historically from the archaeological record so that some could be eliminated. We could then look more closely at the activities which fitted both the changes in the skeleton and the time at which the individual had lived. Pathologies, osteo-arthritis of the joints or enthesopathies, were not of primary consideration. Morphological modifications that develop in response to stresses imposed on the bones during growth are considered to be more reliable indicators of habitual activity. The activities proposed are offered as suggestions only. Much work has still to be done in this field of anthropology, but many of the bones from Ur are so extraordinary that we felt they merited some explanation. A surprising number appear to have laboured hard, carrying heavy loads, on the back or on the head. It is these that form the subject of this paper.

4. THE ROYAL CEMETERY

4. 1. PG1648, THE ATTENDANTS

This tomb was excavated in the 1929-30 season by Max Mallowan. Woolley comments that it was "small and not of great interest, and the bulk of the graves here on what was evidently the outskirts of the old cemetery were poor" (Woolley 1934, 7). It is described as the smallest of the royal tombs, and illustrated in plan (Plate 1 from Woolley 1934, 133). The tomb contained a broken jar of a type (105) imported probably with some special luxury (Woolley 1934, 113, quoted by Reade 2001, 24). Reade proposes that the jars were imported from the middle Euphrates - Khabar region about 2400 -2300BC. And we can ask, consequently carried across the desert on the back of some porter. Against the northwest side of the tomb-chamber were two bodies, those of a very feminine young woman of under 20 years of age, and an older woman; another body lay against the southeast side in the south corner of the chamber. The bones of the body inside the coffin were almost completely decayed and the skull resembled a lump of lime. Reade offers an explanation for the differences in preservation of the grave occupants. The digging and construction work for the tomb would surely have taken more time than was available before the decay of the principal occupant (Reade 2001, 18).

Our studies show that grave PG1648 yielded the remains of at least four individuals: two females and two males. There are also isolated bones of another adult, a child and animals.

4. 2. PG1648a

The skeleton of a young adult or late adolescent female whose bones have been subjected to heat and are discoloured yellowish-brown with a superficial darker brown stain. Breaks of the long bones are concoidal or flat, which is characteristic of heated bone.

The skull bones are much fragmented and no reconstruction was attempted. Physically the bones are gracile, and muscle markings are not pronounced; only the deltoid insertion on the right humerus is well developed. The metacarpals of the left hand are markedly more slender, though not shorter, than those of the right. The cortical bone of the long bones is well developed. The dental and skeletal maturity shows an individual on the brink of full maturity. The third molars have erupted; the basioccipital-sphenoid synchondrosis is complete; the proximal epiphyses of the humeri had recently fused; while those of the ischium were in the process of fusing; the iliac crest is still unfused.

Fragments of cervical and thoracic vertebrae of the spine are present. The uncinate processes of the cervicals are well developed and there is degenerative pitting of the body of C3/C4 indicating disc damage, advanced for the youthful age; both features are perhaps due to carrying loads on the head (Plate 2).

4. 3. PG1648b

The fragmented remains of a mature female, less complete than when seen by Keith. The foot bones, including ankle and metatarsal bones, have traces of a white deposit that resembles adipocere but was identified by infrared spectroscopy as gypsum ($\text{CaSO}_4 \cdot 2\text{H}_2\text{O}$). The cranial sutures are obliterated internally and there are arachnoid depressions; features usually associated with older individuals.

The bones are all gracile without marked muscle impressions; only the neck (capitis) muscles have strong attachment areas. The support of weights carried on the head depends on the posterior neck muscles which are essential in balancing the head. They act like tighteners in the sagittal plane and in multiple oblique planes (Kapandji 1974, 242).

4. 4. PG1648c

This is an adolescent male of about 17 years. The remains comprise the cranium and mandible, six cervical vertebrae including the atlas and axis; left clavicle, and part of the scapula including the glenoid. The bones are fragmented, stained yellowish-brown, without any obvious signs of burning except for the lower right lateral incisor. Parts of the vertebrae are still embedded in the wax used in the field to protect the bones for transport.

4. 5. PG1648d

The skeleton of a mature adult male, including parts of the cervical, thoracic, lumbar and sacral vertebrae; the clavicles; fragments of scapulae and pelvis. The pelvic fragments have very narrow, male type, sciatic notches. All long bones are represented and the bones of the hands and feet. Both patellae are present.

In Keith's description, skull PG 1648c is included with the long bones described here as PG1648d. Keith does not mention any vertebrae nor hand or foot bones. We consider the skull, PG1648c, to be too young for these post-cranial bones, and there is duplication of a cervical vertebra, clavicle and scapula fragments. The bones of the torso (spine, shoulder and hip) are blackened from burning. The long bones and bones of the extremities are coloured yellowish-brown and were presumably fired to a higher temperature.

The vertebral bodies of C6-C7 and Th1 are large; the uncinate processes are not pronounced and the neural arches are rather gracile; C6 is slightly crushed (Plate 3b). In the lower back Th12-L5 are present and fairly complete. They show marked degenerative changes in the bodies and there are additional arthritic changes along the proximal ventral margins of Th12-L4 indicative of disc damage (Plate 3e, f, g). There are arthritic changes to the proximal joints of L3. The sacrum is very straight (Plate 3h). These changes to the spine could be the result of carrying loads persistently from adolescence (Kapandji 1974).

The clavicles have especially deep grooves for insertion of the subclavius muscles. The impression on the conoid tubercle and trapezoid line for the clavicular ligament and for the coraco-costo-clavicular ligament is also marked (Plate 3a). If a heavy load is carried on the back, it tends to pull the scapula away from the clavicle. The trapezoid ligament stabilizes any strain on the acromio-clavicular joint and the costo-clavicular ligament similarly stabilizes the sterno-clavicular joint.

The humerus is robust, with well-developed deltoid impressions. The two ulnas, two radii, and the carpals have a slight lipping of the articular surface margins. The metacarpals of the right hand are complete. The head of metacarpal II is deflected towards the palm. The bone is robust with particularly marked insertions for the 2nd palmar interosseus and the 1st dorsal interosseus muscles, so that there is a ridge between the two on the palmar surface. On the metacarpal III the 2nd and 3rd dorsal interosseus insertions are also marked. The head of MCI (the base of the thumb) is flattened and the proximal phalanx has a marginal tubercle for the adductor pollicis muscle (Plate 3c). This combination of features suggests that the hand was used for gripping – with the fingers splayed – perhaps the straps holding the pack to relieve the weight on the back.

The femora are robust and each has a strong torsion of the head relative to the distal condyles, so that it is anterior to the knee. This form, in bearing a heavy load, would ensure that weight transfer was vertical from hip to knee if the knees were slightly bent. The insertions for the medial and lateral heads of the gastrocnemius muscle are pronounced on the femora implying well developed calf muscles used in flexing the knees when walking.

Both tibia shafts are present and the distal articulation of the right shows medial and lateral squatting facets, which suggests that squatting was the position taken up when at rest. The patellae are notched (vastus notch), a feature that is associated with the pressures imposed on the knee when in a squatting (hocker) position .

The pattern of ligament and muscle development observed on the bones of PG1648d would be those of one who had to carry loads on his back. We have pictorial representations of such porters on the "Peace" side of the Standard of Ur. They carry on the back a great bundle which, like a Stambul porter, is supported by a band across the forehead (Woolley 1934, 273) (Plate 3d). It is possible that PG1648d could have been one such porter.

4. 6. PG211

This burial is tabulated as Period B in Woolley (1934, 420). He noted (BM Ms) that the skull bones showed very distinct signs of pretty hard burning – black all through but not calcined.

The remains consist of the burnt and fragmented skull and pectoral bones of an old adult, possibly female. Suture obliteration and arachnoid depressions in the cranial bones suggest an individual of advanced years. The meningeal vessels are very deeply imprinted on the parietal bones. No teeth are preserved.

She must have been required to lift and carry heavy loads for the glenoid of the scapula is large and shows slight arthritic lipping and there are strongly marked insertion areas on the clavicle for the pectoralis major and sterno-cleido-mastoid muscles and for the conoid ligament.

5. AKKADIAN (SARGONID) DYNASTY

5. 1. PG1483

Woolley recorded that this was an inhumation grave lying NE by SW, head to NE (BM Ms). Not parallel with the two Larsa graves found close by at a slightly higher level. Above the grave were Larsa type pots. The grave is listed by Woolley (1934, 506) in the Sargonid list. The remains of two individuals are present.

5. 2. PG1483a

This is the skeleton of an adolescent 15-16 years old. The skull has a slight saddle depression on the top; the third molars are unerupted and only the proximal epiphyses of the radii and femora have united with the shafts. On the left fibula there are deep attachment areas for the soleus and flexor hallucis longus muscles. The unciolate processes of the cervical vertebrae (which are held together by wax) are pronounced and well developed (Plate 4a), which together with the depression of the skull vault suggests this is possibly another porter using a headband to assist in carrying his load.

5. 3. PG1483b

The fragments of pelvis and long bones of an adult male. The bone is burnt black and mineralized. The femur has a well-developed linea aspera and marked areas on the greater trochanter for the piriformis and gluteus minimus and gluteus medius muscles.

6. LARSA DYNASTY

Old Babylonian people, overthrew Ur, and rebuilt it. They came from the north. According to Keith they were physically smaller and had narrower heads (Keith in Hall and Woolley 1927, 240). Keith commented that they all have long heads of moderate dimensions, with wide but not flat noses. He could not find any series of characters which would demarcate the Larsa men from the usual men of Ur. According to Keith, wherever they came from, they are of the long-headed stock, now represented by Arabs and other long-headed Semites (Keith 1932, in lit. to Woolley). The inhumations were under the floors of the houses. Fragmented remains of seven individuals from the Larsa Dynasty survive. The group includes two females, five males; mostly old or mature to old adults showing signs of strenuous work, particularly load bearing. Grave goods may reflect the occupation in life. A quarter of the town was excavated (Woolley and Mallowan 1976, 15).

6. 1. G43 AH, SKULL a

This was excavated from Room 8 of House 2 and is the relatively complete cranium and mandible of a robust mature male. On the back of the skull, in the nuchal area, deep muscle imprints for the rectus capitis posterior, and the sterno-cleido-mastoid, together with the strongly developed mylohyoid insertion on the mandible suggest that he had carried heavy loads on the back, since these muscles would be tensed to counteract the tendency of the back load to pull the head backwards. It follows that no headband was used in contrast to PG1648d. The deep head of the temporalis muscle has a marked impression on the sphenoid. The cervical vertebrae have well developed unciate processes (Plate 4b).

Unfortunately most of the teeth have been broken off at the crown; however, it can be observed that the wear on the lower molar (36) is unusual in the way that the dentine is worn below the level of the enamel.

6. 2. G43 AH, SKULL b

This was excavated from Room 8 of House 2 (Woolley and Mallowan 1976, 159,198). The cranium and mandible are of an old male. The palate is edentulous and though the cranium is robust, the bones of the face are thin suggesting an individual of advanced years.

6. 3. G48 AH

This is the fragmented skeleton of an aged female, almost certainly over 50 years old, which was excavated from Room 8 of House 2. The body was lying flexed on its left side. She had suffered abscesses around her upper anterior teeth and had lost all her upper anterior teeth and most of her molars (15/32 teeth survive). The limb bones are exceptionally thin and quite unlike any from the Royal Cemetery. Degenerative changes and development of the unciate processes of the cervical vertebrae (especially C3-4) suggest that she habitually carried loads on her head; that these loads were heavy is indicated by the degenerative changes to the lower part of the spine, where some of the vertebral bodies are enlarged along the ventral margin (Scheuermann's disease, Th7-Th11); Th10 also has a depression (Schmorl's node) where the vertebral disc impacted

on the centrum during growth, other vertebrae have collapsed (Th8, 10); and there is evidence of disc damage (L4). The neural spines are particularly long suggesting powerful trapezius muscles (Plate 5d). The attachment areas on the clavicle for the conoid ligament and the trapezius muscle are pronounced; on the humerus the deltoid area is well developed, especially the right, and the medial phalanges of the fingers, especially the index, have pronounced imprints for flexor digitorum superficialis muscles which are used in gripping.

The pattern of muscle development and degenerative changes would be best associated with the habitual carrying of loads probably on the head. Interestingly the muscle insertions in the nuchal area are not pronounced. A stylized version of such a porter may be illustrated by the copper peg shown in Plate 5c.

6. 4. G154 AH

This skeleton was recovered from Room 5 of House 30/A (Woolley and Mallowan 1976, 167, 209). Inside the grave, by the hands of the body, was a large conch shell cut with a trough spout and contained inside it a number of miniature tools (spear, axe) (BM Ms). The bones are very dry and fragile. The skeleton is that of a mature or old adult female – stature 1.52m (5'2"). There has been heavy wear on the teeth and ante-mortem loss. The limb bones are thin. A deep Schmorl's node in the body of Th12, degenerative changes to the discs and joints of the lumbar vertebrae, indicate long-standing strains through lifting and carrying heavy weights. There are accessory sacro-iliac facets on the sacrum and ilia; generally associated with the habit of carrying loads on the back - often a baby slung from a shawl (Kennedy 1989, 155). She has large deep scars of parturition (Pits of Houghton) in the sacral sulcus (Plate 6). Strong imprints on the humerus and clavicle indicate that the deltoid muscles were well developed. The linea aspera on the femur is enlarged. There are squatting facets on the anterior surface of the distal articulation of the tibiae.

6. 5. UNNUMBERED LARSA 1

This is the cranium and mandible of a mature male. The skull is keeled and has very large mastoids. There are strong imprints for the trapezius muscle on the occipital, and also for the posterior part of the digastric, the rectus capitis posterior minor; and there is a deep insertion groove on the sphenoid for the temporalis muscle; which suggest the carrying of loads on the back without the restraining support of a headband (Plate 7).

7. NEO-BABYLONIAN

7. 1. GRAVES 31 AND 32 AND UNNUMBERED BONES

These have not been identified in the Neo-Babylonian grave list published by Woolley and Mallowan (1962). From Woolley's notes it looks as if there were three graves at G31 and G32, i.e. six in all (PG, AH, TW). The remains cannot be matched with the descriptions in Woolley's notes: PG31 TTE only teeth and finger bones remain; PG32 TTE comprised loose bones; G31 AH was a disturbed pot burial; G32 TW was a pot grave of an infant.

The unnumbered bones are a fragmented cranium, mandible and skeleton of an old adult male. The bones are very light. The skull has particularly deep insertion areas for the capitis muscles, and there is evidence, from the attachment area on the right humerus, that the pectoralis major muscle was powerful.

8. DISCUSSION

The extraordinary development of certain muscle imprints on the bones has enabled us to suggest a probable occupation for some of the individuals who were buried at Ur. It implies that their activities were followed intensively, from childhood and for long periods and with little alternative exercise, a concentration that is seen today only among sportsmen and musicians. This role specialization can be taken as reflecting the level of economic activity and urbanization of the communities at Ur. To help us here we have the unique evidence from pictorial representations of people performing tasks that can be directly related to the skeletons that we have to study. The 'Standard of Ur' shows the nation at Peace and at War and we have examples of both among the surviving bones in the collection. A possible charioteer as depicted on the War side has already been described by Molleson and Hodgson (1993). Here we survey the possible evidence for porters as depicted on the Peace side of the Standard and elsewhere.

PG1648d is the best represented skeleton of a group of individuals who were probably similar to the porter shown on the Peace side of the Standard. If he used a head restraint as illustrated this would have encouraged an upright posture and effected the transfer of weight ventrally down the spine. Hence the ventral position of the abnormalities on the lumbar vertebrae and the straightness of the sacrum. The muscles attached to the clavicles were powerful leaving deep impressions, although the bones themselves are not particularly robust. Despite, or perhaps because of, the headband there must still have been considerable muscular tension stabilizing the sterno-clavicular joint. Other porters include G43 AH and Larsa I, although these two do not appear to have used a headband.

A female, G48 AH, from Larsa times seems to have carried loads on her head. The weight of the load can be greater than the body weight of the bearer. The effect of this weight, which is transmitted vertically down the spine is evident in the vertebrae. The unciate processes of the cervical vertebrae, which help stabilize the head, are strongly developed. The thoracic vertebrae show signs of Scheuermann's disease and Schmorl's nodes, developmental conditions associated with weight bearing during growth; other vertebrae are crushed and wedge-shaped. Most remarkable, is the development of the neural spines of the thoracic vertebrae, presumably reflecting the development of the trapezius muscle, which supports the head and has attachments the length of the dorsal spine.

Woolley noticed the continuity of activity from 4,500 years ago to the present day in the role of the porter, carrying large loads on his back, taking some of the strain from a headband, and still to be seen in the streets of middle eastern cities (Woolley 1934). Portage was by many methods - the backpack with or without a headband; loads could be carried on the head or slung over the shoulder; and two porters might carry a load on a pole between their shoulders. Like the female, G48 AH, carrying loads on the head is still the preferred method for women in many parts of the world. Men were occasionally depicted carrying loads on their heads e.g at Khafaje (Early Dynastic III) on a wall plaque but of a decorative subject matter that must have occurred also at

Ur (Lloyd 1984, 115). That such depictions are not more frequent is likely to be for reasons of art composition - the inevitably taller figure distorts the symbolism of the pictorial narrative or must be represented as a very short person. Otherwise it would be tempting to assume that a differentiation in load carrying, by men on the back, by women on the head, had already been established 4000 years ago.

Physically many of the skeletons reflect the importance of human effort in everyday life. There is evidence of social organization and a stratification of society from the skeletal remains. Some of the skeletons do not appear to have undertaken much physical activity at all. These, as would be expected, include Meskalamdug and Queen Pu-abi and this would be consistent with their elite positions. The attendants, PG1648a-d, are an interesting group. Two females, one old one young and two males, also one old one young, were buried in the tomb of a minor royal whose skeleton was not in a suitable condition for study. In this minor tomb we have four main skeletons. The young female, PG1648a shows signs of disc damage to the neck vertebrae, perhaps the consequence of whiplash injury through carrying heavy loads on the head. The older female PG1648b had deep attachment areas for the neck muscles. The young male, PG1648c, shows no signs of heavy work. PG1648d has indications of a very muscular development presumably from long periods of carrying heavy loads.

Crafts were both domestic and state run, although centrally controlled production may have declined after the Ur III period. And there may have been a free labour market in Old Babylonian times (Postgate 1994, 236). Although the five men and two women from Old Babylonian/Larsa times all appear to have carried heavy loads, the small sample limits the value of this work. We cannot test the suggestion that workers and craftsmen lived in specific parts of the city nor that skills were passed from father to son (Postgate 1994, 78) but future excavators might be able to. The generally old, predominantly male Larsa group appears to be a group of workers of low nutritional status. It seems unlikely that this can be entirely attributed to burial practice or excavators' selection.

9. CONCLUSIONS

A reappraisal of skeletal remains excavated in the last century has shown that in spite of the long time since they were found the conclusions of the contemporary specialists can be confirmed in general. Further information as to activity can be surmised using detailed study of bone morphology. The presence of contemporary illustrations made this much more rewarding.

Of course other interpretations of the bone morphologies observed are possible; that is the hazard of this type of work. Perhaps all we have achieved is the identification of some remarkably energetic labourers, who commenced their work at a very young age, whilst the growing bones could respond to the pressures put upon them.

10. ACKNOWLEDGMENTS

Our grateful thanks for assistance in the preparation of this paper are due, in effect, to all the staff of the Department of the Ancient Near East, formerly Western Asiatic Antiquities, The British Museum. Chemical analyses were carried out by Gary Jones, Department of Mineralogy, The Natural History Museum. The photographs were taken by Philip Crabb, Photo Studio, The Natural History Museum, London.

11. REFERENCES

- Hall H.R. and Woolley C.L. 1927 *The Ur Excavations Volume I Al-'Ubaid*. Oxford University Press, 244pp.
- Kapandji I.A. 1974 *The Physiology of the joints Volume 3*. Churchill Livingstone.
- Kennedy K.A.R. 1989 Skeletal markers of occupational stress. in Iscan M.Y. and Kennedy K.A.R. (eds) *Reconstruction of life from the skeleton*. Alan Liss, 129-160.
- Lloyd, S. 1984 *The Archaeology of Mesopotamia*. Thames and Hudson, London, 251pp.
- Molleson T. and Hodgson D. 1993 A cart driver from Ur. *Archaeozoologia*, 6, 93-106.
- Postgate J.N. 1994 *Early Mesopotamia: society and economy at the dawn of history*. Routledge London 367pp.
- Reade J. 2000 *Mesopotamia*. British Museum Press, London, 2nd Edn 96pp.
- Reade J. 2001 Assyrian King-lists, the Royal Tombs of Ur, and Indus origins. *Journal of Near Eastern Studies* 60: 1-29.
- Woolley C.L. 1934 *Ur Excavations The Royal Cemetery 2 vols*. Publications of the Joint Expedition of the British Museum and of the University of Pennsylvania to Mesopotamia, 604pp.
- Woolley C.L. and Mallowan M.E.L. 1962 *Ur Excavations Volume IX The NeoBabylonian and Persian Periods*. Publications of the Joint Expedition of the British Museum and of the University of Pennsylvania to Mesopotamia, 604pp.
- Woolley C.L. and Mallowan, M.E.L 1976 *The Excavations at Ur 1926-7 Volume VII, The Old Babylonian Period*. Publications of the Joint Expedition of the British Museum and of the University of Pennsylvania to Mesopotamia, London/ Philadelphia, 199.
- Woolley L. and Moorey P.R.S. 1982 *Ur 'of the Chaldees'*. The final account revised and updated. The Herbert Press, London, 272pp.




Plate 1. Plan of tomb PG1648 shows the sacrificed attendants surrounding the burial of a minor royal. It sketches the remains of only three attendants, but does show the wealth of bowls and jars, some of them imported (Woolley 1934).



Plate 2. Evidence of disc damage on a neck vertebra (C3) from PG1648a a young female. The body of the vertebra is eroded and pitted where the cartilaginous disc has been damaged. This could be the consequence of whiplash injuries while carrying loads. (The ventral part of the body and the articular joints show post mortem damage).

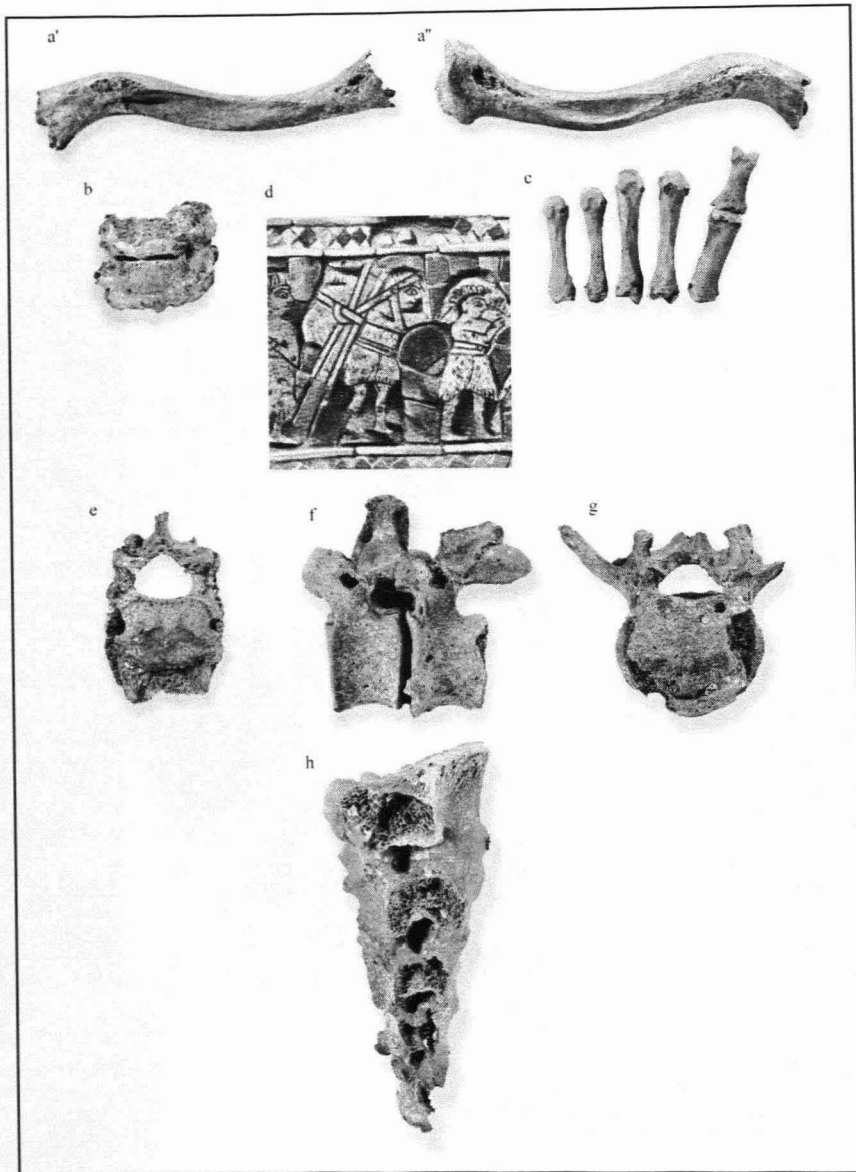


Plate 3. Evidence that the attendant PG1648d carried heavy loads on his back. a). The two clavicles of PG1648d have pronounced areas for the costo-clavicular ligament which ties the clavicle to the underlying costal cartilage and thereby acts to stabilize the sterno-clavicular joint. The strong imprints for the trapezoid and conoid ligaments also tie the lateral head of the clavicle to the conoid process of the scapula and stabilizes the acromo-clavicular joint. The subclavius muscle and clavi-pectoral fascia which control excessive movement of the clavicle have a deep area of attachment mid-shaft. These features must result from the habitual carrying of heavy loads in a backpack. b) Neck vertebrae (C6, 7) with extensive spondylitic growth along the ventral margin of the bodies. c). Bones of thumb and palm (metacarpals) of the right hand (ventral view). The metacarpals have developed a ridge between the insertions of the interosseous muscles, which must have been extra large. Note the prominent tubercle (medial) for adductor pollicis, on the first phalanx of the thumb. d). A 'Sambul porter' from The Standard of Ur. The enormous load is suspended from a headband which the porter grips with his hands to take some of the strain (Detail from the peace side of the 'Standard of Ur' from Woolley 1934). e, g) Proximal views, of Th12 and L4, with, ventrally, evidence of extreme disc damage. f) Side view of lumbar vertebrae (L1, L2) showing the development of bony growths (spondylosis) on the vertebral body. If the damage was caused by heavy loading on the spine, as from a backpack, it suggests that a headband was used since the weight is then transferred down the front of the spine. h). Side view of the unusually straight sacrum. The straightness must be a response to loading on the lower spine.

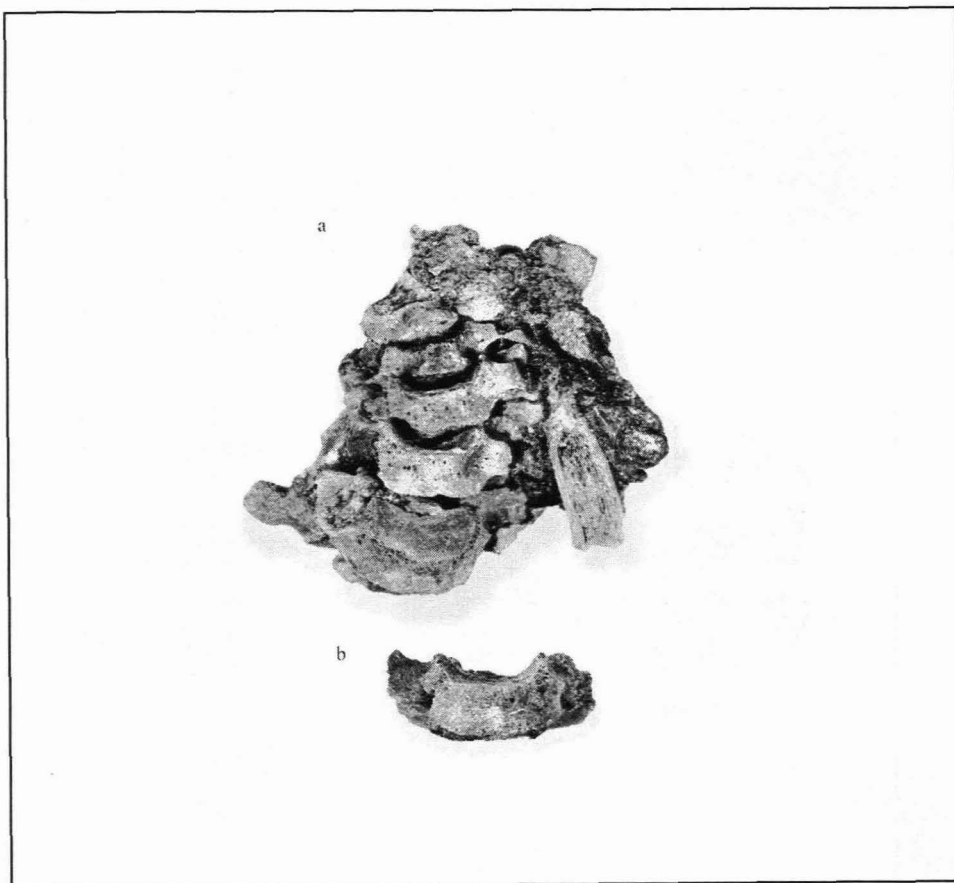

Plate 4. The uncinate processes on the neck vertebrae help in supporting the head. They are well developed in many of the individuals from Ur. a) Cervical vertebrae of PG1483a still held by wax applied during excavation. The strong development of the uncinate processes is clear. b) Vertebral body (lacking neural arch) from G43 AH, with pronounced uncinate processes.



Plate 5. Evidence of disc damage to the spine of G48 AH a, b) The third and fourth cervical vertebrae are eroded and pitted probably the result of damage to the cartilaginous disc through whiplash injuries. c) Copper peg depicting a woman carrying a load on her head, which she supports with her hand (From Uruk reign of Ur-Nammu c.2018-2001 BC, Reade 2000, 79). d) Thoracic vertebrae (Th8-11) showing the long neural spines and partial collapse of Th8 and Th10. e) Distal view of Th10 showing Schmorl's node in the vertebral body and Scheuermann's disease of the ventral margin. Both conditions are associated with load bearing during growth.

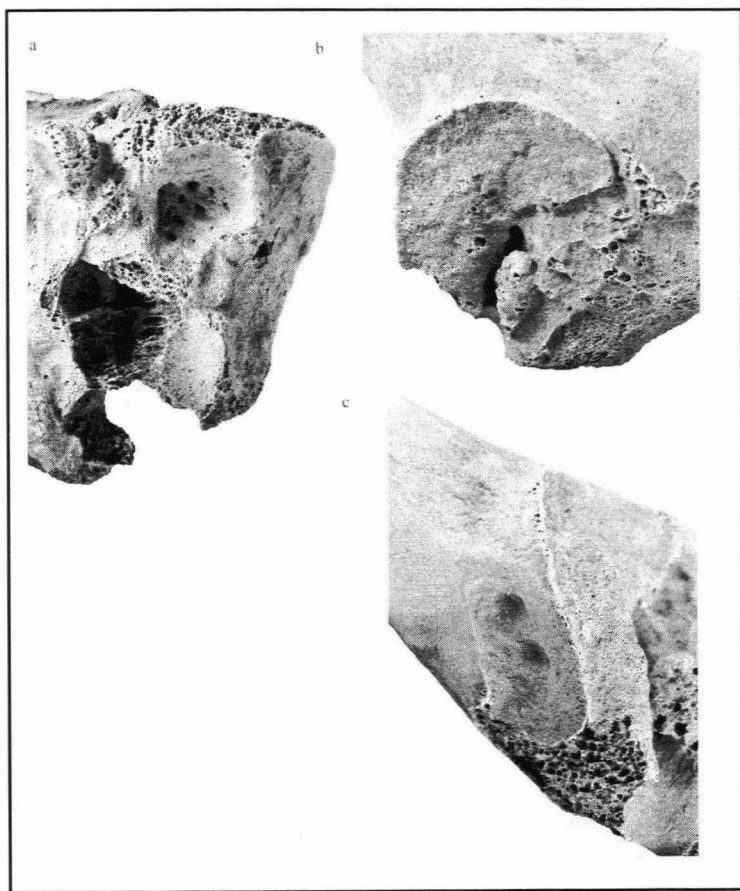


Plate 6. The female G154 AH illustrates the impact on the pelvis of weights carried low on the back. a) Accessory facet dorsal to the sacroiliac articulation on the sacrum (right side). b) Corresponding accessory facet on the ilium above the articular surface. c) Pits of Houghton in the sulcus of the greater sciatic notch (right side).

Plate 7. Larsa 1 unnumbered, cranium of a male with large mastoid processes (a) and prominent insertion areas for the trapezius, semispinalis capitis, and rectus capitis posterior muscles that support the head (b). These head muscles would be strongly developed when required to support heavy loads carried on the back without the aid of a headband. c) Ivory intaglio showing a porter with an immense load on his back but, apparently, no head restraint (from Woolley 1934, Pl.94).

