

Work- and age-related changes in an Iron Age horse skeleton from Danebury hillfort, Hampshire

ROBIN BENDREY

Department of Archaeology, Faculty of Social Sciences, University of Winchester, West Hill,
Winchester, Hampshire, SO22 4NR, UK.

e-mail: robin.bendrey@winchester.ac.uk

(Received November 4, 2005; Revised April 20, 2007; Accepted May 22, 2007)



ABSTRACT: Pathological changes and other alterations in an Iron Age horse skeleton from Danebury, Hampshire, England are described and used to interpret the possible use of the animal. The low level of pathology present in what is a relatively old animal (*c.*16-18 years of age at death) suggests that the horse was not heavily used, perhaps employed to pull a light cart or chariot or occasional riding. The presence of a horizontal fissure in the caudal epiphysis of the thoracic vertebra 14 may indicate that it was used for riding, possibly with either a pad saddle or bareback.

KEYWORDS: HORSE, PALAEOPATHOLOGY, IRON AGE, DANEbury, RIDING, TRACTION

RESUMEN: El trabajo aborda los cambios patológicos y otro tipo de alteraciones detectados en un esqueleto de caballo de la Edad del Hierro recuperado en Danebury, Hampshire, Inglaterra y utiliza ello para interpretar los posibles usos del animal. El limitado grado de patología existente en lo que parece ser un animal bastante viejo (entre 16-18 años de edad) sugiere que el caballo no fue utilizado de forma intensiva siendo su misión, posiblemente, la de tirar de un carro o carroza ligera o, incluso, ser montado de forma ocasional. La presencia de una fisura horizontal en la epífisis caudal de la vértebra torácica nº 14 podría indicar que se utilizó para la monta bien a pelo o con silla de montar.

PALABRAS CLAVE: CABALLO, PALEOPATOLOGÍA, EDAD DEL HIERRO, DANEbury, MONTA, TRACCIÓN

INTRODUCTION

This article describes pathological changes and other alterations in a horse skeleton from Danebury, an Iron Age hillfort in Hampshire, England (Cunliffe, 2003). The skeleton under study derives from pit 562 (context 3) and is dated to the middle phase of activity at the site, c.310-270 BC (Cunliffe, 2003). The site produced a range of animal bone deposits from disused grain storage pits interpreted as evidence for ritual behaviour, of which this skeleton is one such example (Grant, 1984). Other classes of specially deposited material identified at Danebury consist of groups of pots, iron implements, horse and vehicle trap-pings, layers of burnt grain and human remains (Cunliffe, 2003).

THE SKELETON

The skeleton is that of an adult male horse, based on the presence of well-developed canines and the shape of the pelvis (Sisson & Grossman, 1966). Analysis of lower incisor wear indicates an age of around 16 to 18 years at death (Cornevin & Lesbre, 1894). The cranium of the animal is missing. There is an empty bag in the storage boxes containing the skeleton labelled as containing the cranium, and it is assumed that this part has been removed post-excavation and that the skeleton was originally complete.

The mandible

For the past forty years, research into bit wear in horses –to identify that animals were bitted– has focussed on changes causing bevelling on the lower second premolar (P_2) anterior corner (e.g. Bökönyi, 1968; Clutton-Brock, 1974). Bit wear analyses were developed and refined by Anthony and Brown (Anthony & Brown, 1991, 1989, 2003; Brown & Anthony, 1998). They define bit wear as the damage that occurs on the occlusal surface of the second premolars when a horse chews the bit, and developed a macroscopic methodology for recording the presence of bevelling on the lower second premolars (Brown & Anthony, 1998). This method has been criticised, as abnormal occlusion with the upper tooth can cause a bevel on the P_2

anterior corner (Levine *et al.*, 2002: 69 and figure 17; Benecke & von den Driesch, 2003: 79; Olsen, 2003: 101). Qualitative changes to the occlusal surface can also be used as supportive evidence for biting (e.g. Albarella *et al.*, 1997: 43; Olsen, 2006: 254-255), but the use of a bevel measurement alone as evidence for biting without comparing the lower second premolar (P_2) against the occluding lower second premolar (P^2) is insecure (Bendrey, forthcoming).

The bevel measurement method cannot be used on the Danebury horse, due to the absence of the upper dentition and the problems set out above. In addition, there are no macroscopic qualitative changes, such as the absence or reduction of the «Greaves' Effect», the natural process whereby the softer dentine is worn down faster than the harder enamel, leaving raised enamel ridges on the occlusal surface (contact with a metal bit causes both the enamel and dentine to wear down to a similar level) (see Olsen, 2006: 254-255). There is, however, evidence for biting damage to the lower second premolars (P_2 s) in the form of a band of enamel exposed on the anterior edge of each tooth (Figure 1). Bendrey (in press) argues that such bands of enamel exposure on the 'front', or anterior, edge of equid lower second premolars derive from a bit coming into contact with the front edge of the tooth and wearing away a strip of cementum to expose the enamel beneath (more severe biting damage can also expose areas of dentine). Not all enamel exposure on the anterior border of P_2 s can be considered as evidence for biting, as this is a relatively exposed site and other forms of damage can occur. Bendrey (in press) suggests that to interpret such enamel exposure on the anterior edge of P_2 s as evidence for biting damage the following criteria must be met: the height of this exposure should be in excess of 5mm (measured from the occlusal surface towards the mandible); anterior exposure must not be similar to, or less than, any exposure on the lingual or buccal sides; the form of exposure should be an approximately parallel-sided band. All these criteria are met for the specimens from pit 562, for which the height of the anterior enamel exposure (measured from the occlusal surface towards the mandible) is 6.8 mm for the left LP2 and 9.9mm for the right. The presence of biting damage on the P_2 s indicates that the animal was harnessed with a bit, and was therefore used for either riding or driving.

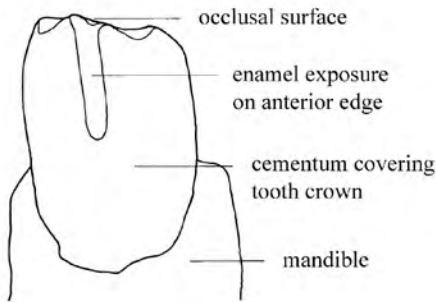


FIGURE 1

Anterior view of left lower second premolar (P_2) exhibiting anterior enamel exposure suggestive of biting damage (above), with annotated drawing (below) [see Bendrey (in press) for discussion of biting damage].

The hip and shoulder

There is slight lipping of the rim of the left and right acetabuli. Although shoulder and hip injuries may be characteristic of traction (Levine *et al.*, 2000), the slight changes observed to the acetabuli are not strong evidence for traction compared to, for example, the eburnation that is sometimes seen in cattle acetabuli (e.g. Groot, 2005), and may be related to other factors, such as age. Indeed, comparable changes have been observed by the author on Przewalski's horse skeletons [in the National Museum, Prague; the collection studied in Bendrey (2007)] that have not been worked.

The fore-limbs

Bony changes in the fore-limbs are restricted to the lower leg bones (the metacarpals and phalanges). New bone deposition has bridged the interosseous border between metacarpal iii and the medial and lateral accessory metacarpals in the right fore-limb (Figure 2); as it has between the metacarpal iii and the medial accessory metacarpals in the left fore-limb (the other metapodials in this horse remain unattached). The ossification of the interosseous lig-



FIGURE 2

Proliferative new bone formation has bridged the interosseous border between the right metacarpal ii and metacarpal iii (lateral view).

aments between the metapodials in horses, a condition known as splints, occurs as a response to the repeated movements of the bones, causing damage to the connecting ligaments and periosteum of the bones, ultimately leading to their ossification (Bertone, 2002). Splints is known to be, in part, age-related, and that in the metacarpals fusion progresses normally with ageing, although as stated it may also be the result of bone disease (Bertone, 2002). The expression of the ossification of the interosseous ligaments in this animal is consistent with the pattern identified in a population of unworked Pzrewalski's horses (Bendrey, 2007). The bony change is known to manifest itself earlier in the fore-limbs and the medial accessory metapodials.

The anterior proximal phalanges exhibit bilateral osteophytosis of the distal abaxial borders in the insertion of the collateral ligaments of the interphalangeal joint (Figure 3). The identification of these lesions in the fossil equid record indicates that this is a naturally occurring condition (Rooney, 1997).

The hind-limbs

Beyond the slight remodelling of the acetabuli noted above, changes in the hind-limbs are also recorded to the hock joints. In the left hind-limb the central, third, and first and second tarsals are ankylosed; and in the right the central and third tarsal are ankylosed and there is also some new bone formation on the fourth, and first and second tarsals. The articular surfaces are unaffected, and there is deposition of osteophytes around the articulations of the tarsals and the proximal metatarsals (Figure 4). This is a case of bone spavin [see Sullins (2002) for discussion of different forms of spavin].

Bone spavin is an osteoarthritis and periostitis that involves the distal intertarsal, tarsometatarsal, and occasionally the proximal intertarsal joints (Sullins, 2002: 931). A number of possible, probably inter-related, causes of spavin include hereditary factors that affect conformation, severe concussion (due to faulty conformation, faulty



FIGURE 3

Anterior proximal phalanx exhibiting bilateral osteophytosis of the distal abaxial borders in the insertion of the collateral ligaments of the interphalangeal joint (arrowed).

shoeing, heavy work, or working on hard surfaces), and rotation of the lower limb from the hock downwards (Baker & Brothwell, 1980: 118).

There are also small areas of abnormal bone remodelling on the medial aspect of the anterior part of each proximal metatarsal (Figure 4). These areas extend some 3.5 cm in length distally, and do not reach the proximal articular surface. The symmetrical nature of these changes would argue against a fracture, or other traumatic injury, as a cause. A diagnosis of the possible cause/s of this bony change has not been possible.




FIGURE 4

Anterior view of right proximal metatarsal and tarsals (above) and close-up of new bone formation on right proximal metatarsal (below).

The spinal column

A number of pathological changes are recorded in the vertebral column. Tables 1 and 2 compare abnormalities of thoracic vertebrae 11-19 of the Danebury horse with an Iron Age skeleton from *Archaeofauna* 16 (2007): 73-84

Blewburton Hill, Oxfordshire examined by the author (Bendrey *et al.*, forthcoming), Early Iron Age horses from Ak-Alakha 5 (Altai) and Lisovichi (Ukraine), modern free-living Exmoor ponies and medieval horses from Ak-Alakha 1 (Altai) published by Levine (2004, 2005). The four Scytho-Siberian horse skeletons from Ak-Alakha 5 (Altai), date to the fifth to third century BC, and the contexts of these burials suggest that they were riding animals (Levine, 2005).

Spondylotic spurs of new bone are recorded at the cranial edge of the ventral surface of the centra, adjacent to the intervertebral space, on thoracic vertebrae 13 and 14 (Figure 5). Lumbar vertebrae 2 and 3 also exhibit slight deposition of spondylotic spurs of new bone at the cranial edge of the ventral surface of the centra, adjacent to the intervertebral space. Deposition of spondylotic spurs of new bone on the ventral and lateral surfaces of the vertebral bodies adjacent to the intervertebral space (Table 2, lesion 1) and impinging or overriding spinous processes (Table 2, lesion 2) are known to be connected with natural ageing processes, congenital defects and are thought to be linked to riding (Levine *et al.*, 2000). Comparison with the Exmoor pony skeletons described by Levine (2004) suggests that the presence of lesion 1 in the Danebury animal may be a naturally occurring abnormality.




FIGURE 5

Spondylotic spurs of new bone (arrowed) at the cranial edge of the ventral surface of the centra, adjacent to the intervertebral space, on thoracic vertebrae 13 and 14.

Lumbar vertebrae 4 and 5 are fused together at the left transverse processes (the right side are missing): the fused processes appear to have also

	Danebury	Blewburton Hill
Context number	P562.C3	Cutting F
Age (years)	16-18	6
Sex	Male	Female
Number of thoracic vertebrae	18	18
Lesion 1) Deposition of spondylotic spurs of new bone on the ventral and lateral surfaces of the vertebral bodies adjacent to the intervertebral space	T13 and 14, slightly developed (see Figure 5)	Not present
Lesion 2) Impinging or overriding spinous processes	Unclear due to damaged bone	Not present
Lesion 3) Horizontal fissures through the caudal epiphysis	T14 (see Figure 7)	Not present
Lesion 4) Periarticular osteophytes	Not present	Not present

TABLE 1

Description of abnormalities of thoracic vertebrae 11-18 of Iron Age southern British horses: comparison of Iron Age horse from Danebury, Hampshire with Iron Age horse from Blewburton Hill, Oxfordshire.



FIGURE 6

Fusion of lumbar vertebra 6 and sacrum at the lateral joints and lateral edges of the centra (arrowed).

broken and subsequently re-united during the healing process. In a study of ankylosing lesions in the spine of 245 equid skeletons, Stecher & Goss (1961) identified that the lateral joints of lumbar vertebrae transverse processes were only fused in domestic equids and not wild ones, suggesting that it is related to increased stresses on the skeleton associated with riding or traction, although it may be partially related to age (Rackham, 1995).

Lumbar vertebra 6 is fused to the sacrum at the lateral joints and the lateral edges of the centra (Figure 6). In their study, Stecher & Goss (1961) state:

Ankylosis, fusion, or significant spur formation was not seen between the last lumbar vertebra and the sacrum ... significant flexion of the lower spine is possible only between the last lumbar vertebra and the sacrum. This flexion is limited but it is important and it is never impaired. On the other hand, flexion of the lumbar spine is restricted and further stabilization by fusion of the fifth and sixth lumbar vertebrae seems to be advantageous.

The extent to which the ankylosis of the lumbar vertebra 6 and sacrum is age- or work-related, or is a congenital abnormality, is uncertain. The absence of new bone formation around the ankylosed joint suggests that it may be the latter.

A horizontal fissure through the caudal epiphysis was noted on thoracic vertebra 14 (Figure 7). These lesions only occur in the Early Iron Age horses and not the free-living Exmoor ponies (Table 2) and are therefore considered as work-related changes (Levine *et al.*, 2000; Levine, 2004).

DISCUSSION

AGE-RELATED CHANGES

Several of the observed changes can be considered as age-related. The pattern of ossification of the accessory metapodials to the cannon bones in the lower limbs of the animal is comparable with that recorded for a sample of unworked Przewalski's horses: in that the condition is more pronounced in the fore-limbs than the hind-limbs and also in the medial metapodials rather than the lateral metapodials (this is thought to be related to Archaeofauna 16 (2007): 73-84



FIGURE 7

Caudal view of thoracic vertebra 14 showing horizontal fissure through the epiphysis.

how the weight of the animal acts through the legs) (Bendrey, 2007). Also, the bilateral osteophytosis of the proximal phalanges and the lipping of the acetabula rims are also noted in the same sample of Przewalski's horses; although all these conditions may also be exacerbated by work.

In the Danebury horse, the deposition of slight spondylotic spurs of new bone on the ventral surfaces adjacent to the intervertebral space of the thoracic vertebrae 13 and 14 (Figure 5; Table 1, lesion 1) may be an age-related change. This animal is reasonably old, aged *c.*16-18 years at death, and this pathology is absent from the younger horse from Blewburton Hill, aged *c.*6 years at death. Comparison with data from the free-living Exmoor ponies published by Levine also supports this (Table 2), in that this change is absent in the younger animal (12 years old) but present in the older (27 years old).

WORK-RELATED CHANGES

A number of features in the skeleton can be interpreted as work-related changes. The identifi-

	Ak-Alakha 5 (Altai)		Lisovichi (Ukraine)		Ak-Alakha 1 (Altai)		Exmoor ponies	
Horse no.	1	2	3	4	1	1	2	
Age (yrs)	16+	10-15	10½	7-10	11½	11 years	10½ years	97/7
Sex	Male	Male	Male	Male (possible gelding)	Male (probable gelding)	Male	Male	Female
No. of TV	18	19	18	18	18	18	18	18
Lesion 1) Deposition of spondyloitic spurs of new bone on the ventral and lateral surfaces of the vertebral bodies adjacent to the intervertebral space	T11 to 18	Increasing from T11 to T14 (11 & 12 caudal; 13 & 14 cranial + caudal)	T14, 17, 18 strongly developed; T15 weakly developed	T13 to 15 most strongly developed, but extends to T17	T10 to 18; T13 to 18 most strongly developed	T14, small ventral spondyloitic spur	Not present	Slightly developed, T12-14
Lesion 2) Impinging or overriding spinous processes	T16-18 (possibly T15 also)	T14-15 probably; T15-19 possibly	Unclear because of poor preservation	T10-12 probably	T10-12; 13-15 Otherwise unclear because of poor preservation	Spines crowded together and T13-16 have been touching, no significant overriding	Not present	Not present
Lesion 3) Horizontal fissures through the caudal epiphysis	T13 and 15, caudal	T13 and 14, (most developed on T14), caudal	T14, caudal; T18, cranial	T13 and T14, (most developed on T14), caudal	T18, caudal	Not present	Not present	Not present
Lesion 4) Periarticular osteophytes	T16-17 small osteophytes	T15-T18 small osteophytes	T17, 18 small osteophytes	Osteophytes, increasingly from T14 to T17, the decreasing	Osteophytes on T16, 17. Otherwise unclear because of poor preservation	Slight erosion and pitting of articular facets between T14 & 15, T15 & 16, T17 & 18	Some fairly insignificant bony thickening on the processes between T13 & T14, T14 & T15	Not present
								T11-18 small osteophytes

TABLE 2

Description of abnormalities of thoracic vertebrae 11-19 of: Early Iron Age horses from Ak-Alakha 5 (Altai) and Lisovichi (Ukraine); medieval Turkic horses from Ak-Alakha 1 (Altai); and modern free-living Exmoor ponies. Information from Levine *et al.* (2000) and Levine (2004, 2005).

cation of biting damage to the lower second premolars (Figure 1) indicates that the animal was bitted, and was used for either riding or traction. Another non-specific indicator of work may be the fusion of the lateral joints of lumbar vertebrae transverse processes. Other changes in the postcranial skeleton may be used to further refine the interpretation of use.

Levine *et al.* (2000) suggest that the high incidences of horizontal fissures through caudal epiphyses of thoracic vertebrae in the Scythian horses (Table 2) may be related not just to the fact that they were ridden, but also to the way that they were ridden. The Pazryk culture used pad saddles, which were in essence two leather cushions [see Levine *et al.* (2000) for a more detailed description]. Levine *et al.* (2000) hypothesize that the weight of the rider, acting on the dorsal processes of the caudal thoracic vertebrae through the pad saddle, could have been an important factor in the types of lesions identified in the Early Iron Age animals (Table 2). These saddles differ from frame saddles in that the weight of the rider acted directly onto the spinous processes of the thoracic vertebrae through the pad saddle, whereas the frame saddle had no contact with the thoracic vertebrae (Levine *et al.*, 2000). Through comparison of these Early Iron Age horses, which wore pad saddles, Medieval Turkic horses, which wore frame saddles and modern free-living Exmoor ponies, which were never saddled, Levine (2005) suggests that these abnormalities are associated with pad saddles and probably with riding bareback (Table 2). The identification of a horizontal fissure in one of the caudal thoracic vertebrae from the Danebury horse raises the possibility, therefore, that the Danebury horse was ridden with a pad saddle or perhaps bareback.

The changes in the caudal thoracic vertebrae on the Danebury horse are less severe than those recorded in the Ak-Alakha and Lisovichi animals; in fact those noted, except for the horizontal fissure in thoracic vertebra 14, are within the range of changes noted in the Exmoor ponies. The milder extents of the lesions, in this relatively old animal, indicate a 'lighter' use of the animal; perhaps pulling a light chariot/cart or if it was ridden, linked to the style or duration of riding. Table 1 compares the abnormalities in the Danebury horse to a horse skeleton excavated from cutting F at Blewburton Hill, Oxfordshire, another Iron Age hillfort (Collins, 1952). The low level of abnormalities present in the Blewburton Hill horse th-

Archaeofauna 16 (2007): 73-84

racic vertebrae (Table 1) was generally reflected in the rest of the skeleton of this animal (Bendrey *et al.*, forthcoming). Even though it is a relatively young animal, at six years of age at death, this supports the picture suggested by the Danebury horse of the relatively 'light' use made of southern British Iron Age horses.

The Ak-Alakha 5 horses all had fairly severe spondylotic spurs on the vertebrae that possess the fissures (and in adjacent vertebrae), whereas the spondylotic spurs on the Danebury specimen are only very minor (Figure 5). These may reflect differences in the level, as well as type, of use of the animals: the Early Iron Age Ak-Alakha peoples were a nomadic society that, from the level of abnormalities in the animals, made more intensive use of horses than the Iron Age peoples of southern Britain, who were sedentary farmers. None of the pathologies in the Danebury skeleton indicate a particularly heavy use of the horse, for example ploughing, and the good condition of the horse skeleton, at this advanced age, indicates only light use perhaps for pulling a light chariot/cart or occasional riding. As discussed above the horizontal fissure in thoracic vertebra 14 could suggest the latter.

ARCHAEOLOGICAL CONTEXT: THE SOUTHERN BRITISH IRON AGE

It is the case that the literature places far greater emphasis on the use of Iron Age horses for pulling chariots and carts than for riding; largely, it seems, based on finds of two-wheeled vehicles in 'Arras culture' burials concentrated in Yorkshire, finds of vehicle fittings on a range of sites and Julius Caesar's descriptions of British warfare techniques (Cunliffe, 1991: 379 and 491-492; Cunliffe, 2003: 73-74 and 163). Such discussions, therefore, are not based on the evidence of Iron Age horses themselves, but rather on other sources, that may be more appropriately considered as evidence for a restricted elite burial rite (Cunliffe, 1991: 503), evidence for deliberate deposition of vehicle fittings (Cunliffe, 2003: 147) and evidence for the practice of Iron Age warfare, respectively. The archaeological visibility of chariots, therefore, are based on evidence heavily biased by elite associations and religious beliefs, and is not representative of the everyday functioning of an agricultural society. Also, many of the accoutrements of riding may not be archaeologically visible, for example if saddles

were made of perishable materials, or if horses were ridden bareback. As such the importance of riding has probably been under-represented.

The work of Levine and colleagues, however, has provided a methodological basis whereby the uses of horses can be considered on the evidence from horse bones themselves, through the study of bony changes in the post-cranial skeleton. Although the choice of animals deposited also probably represents a biased sample, this method does look directly at the horses themselves. The application of this method to the Danebury animal indicates that the horse may have been used for riding. It must be remembered that the comparative sample size is small (Table 2), but it will only be through the publication of horses from different areas and periods that greater understanding of the development of these lesions will be achieved.

The importance of horses for riding can be envisaged in a number of areas. From the later Bronze Age onwards, as land was subdivided by boundaries and field systems and farmed (Yates, 2001; Cunliffe, 2004), horse riding may have allowed speedy and efficient access to pastoral and arable lands utilised by settlements. Cunliffe (1991: 492) states that although vehicles are known from the Hallstatt period on the continent, there is no evidence for their use in Britain at this time (the Late Bronze Age in Britain), and suggests that the light two-wheeled vehicle was probably introduced to Britain during the La Tene I period, in the late fifth or early fourth century BC. Presumably, therefore, functional use of the horse before this, without wheeled vehicles, would have consisted of riding, pulling loads without wheels or pack-use.

Horses, perhaps used to manage, and transport, agricultural and other resources, could also have been used to manage territorial control. In Middle Iron Age Wessex a small number of developed hillforts, such as Danebury and Maiden Castle, Dorset, rose to prominence over weaker settlements, establishing large controlled territories (Haselgrove, 1999). In such a scenario the speed, mobility and distances of travel enabled by horse riding could have been important for maintaining territorial control.

CONCLUSION

A number of features of the Danebury skeleton are important in interpreting the use made of the

horse during its life. These are the enamel exposure on the anterior edge of the lower second premolars, the general low level of vertebral pathology and the presence of the horizontal fissure in the caudal epiphysis of thoracic vertebra 14.

The enamel exposure on the anterior edge of the lower second premolars is interpreted as damage caused by biting, following Bendrey (in press), which indicates that the horse had been used for either riding or traction. The low level of pathology present in the Danebury horse, considering that it is a relatively old animal (*c.*16-18 years of age at death) suggests that the horse was not heavily used, perhaps employed to pull a light cart or chariot or occasional riding. The presence of a horizontal fissure in the caudal epiphysis of the thoracic vertebra 14 may indicate that it was used for riding, with either a pad saddle or bareback.

It is suggested that the importance of riding in the Iron Age has probably previously been under-represented in the literature, largely due to the archaeological visibility of vehicles and vehicle fittings and invisibility of riding, due to perishable materials. This can now be reassessed based upon the foundation of the methodological work and comparative analysis of Levine and colleagues (Levine *et al.*, 2000).

ACKNOWLEDGEMENTS

I would like to thank Marsha Levine and Katherine Whitwell for discussing their work and the skeleton with me and Kay Ainsworth and David Allen (Hampshire County Council Museums Service) for allowing me access to the Danebury archive.

REFERENCES

- ALBARELLA, U.; BEECH, M. & MULVILLE, J. 1997: The Saxon, medieval and post-medieval mammal and bird bones excavated 1989-1991 from Castle Mall, Norwich (Norfolk). English Heritage AML report 72/97, London.
- ANTHONY, D.W. & BROWN, D.R. 1989: Looking a gift horse in the mouth: identification of the earliest bitted equids and the microscopic analysis of wear. In: Crabtree, P.J.; Campana, D. & Ryan, K. (eds.): *Early animal domestication and its cultural context*: 99-114. *Archaeofauna* 16 (2007): 73-84

116. MASCA Research Papers in Science and Archaeology, Special Supplement to Volume 6, Philadelphia.
- ANTHONY, D.W. & BROWN, D.R. 1991: The origins of horseback riding. *Antiquity* 65: 22-38.
- ANTHONY, D.W. & BROWN, D.R. 2003: Eneolithic horse rituals and riding in the steppes: new evidence. In: Levine, M.; Renfrew, C. & Boyle, K. (eds.): *Prehistoric steppe adaptation and the horse*: 55-68. McDonald Institute for Archaeological Research, Cambridge.
- BAKER, J. & BROTHWELL, D.R. 1980: *Animal diseases in archaeology*. Academic Press, London.
- BENDREY, R. in press: New methods for the identification of evidence for biting on horse remains from archaeological sites. *Journal of Archaeological Science*.
- BENDREY, R. 2007: Ossification of the interosseous ligaments between the metapodials in horses: a new recording methodology and preliminary study. *International Journal of Osteoarchaeology* 17: 207-213.
- BENDREY, R.; LEACH, S. & CLARK, K.M. forthcoming: New light on an old rite: reanalysis of an Iron Age burial group from Blewburton Hill, Oxfordshire. In: Morris, J. & Maltby, J.M. (eds.): *Perceiving ritual activity through environmental archaeology*. B.A.R. (International Series), Oxford.
- BENECKE, N. & VON DEN DRIESCH, A. 2003: Horse exploitation in the Kazakh steppes during the Eneolithic and Bronze Age. In: Levine, M.; Renfrew, C. & Boyle, K. (eds.): *Prehistoric steppe adaptation and the horse*: 69-82. McDonald Institute for Archaeological Research, Cambridge.
- BERTONE, A.L. 2002: The metacarpus and metatarsus. In: Stashak, T.S. (ed.): *Adams' lameness in horses*: 800-830. Lippincott Williams & Williams, Philadelphia. Fifth edition.
- BÖKÖNYI, S. 1968: Mecklenburg collection, part 1: data on Iron Age horses of central and eastern Europe'. *American School of Prehistoric Research, Peabody Museum, Harvard University, Bulletin* 25: 3-71.
- BROWN, D. & ANTHON, Y D. 1998: Bit wear, horseback riding and the Botai site in Kazakhstan. *Journal of Archaeological Science* 25: 331-347.
- CLUTTON-BROCK, J. 1974: The Buhen horse. *Journal of Archaeological Science* 1: 89-100.
- COLLINS, A.E.P. 1952: Excavations on Blewburton Hill, 1948 and 1949. *Berkshire Archaeological Journal* 53: 21-64.
- CORNEVIN, C. & LESBRE, X. 1894: *Traité de l'âge des animaux domestiques: d'après les dents et les productions épidermiques*. Librairie J.-B. Baillière et Fils, Paris.
- CUNLIFFE, B. 2004: Wessex Cowboys. *Oxford Journal of Archaeology* 23(1): 61-81.
- Archaeofauna 16 (2007): 73-84
- CUNLIFFE, B. 2003: *Danebury Hillfort*. Tempus, Stroud.
- CUNLIFFE, B. 1991: *Iron Age Communities in Britain*. Routledge, London.
- GRANT, A. 1984: Animal husbandry. In: Cunliffe, B.: *Danebury: an Iron Age hillfort in Hampshire*: 496-548. Council for British Archaeology Research Report 52. Council for British Archaeology, London.
- GROOT, M. 2005: Palaeopathological evidence for draught cattle on a Roman site in the Netherlands. In: Davies, J.; Fabiš, M.; Mainland, I.; Richards, M. & Thomas, R. (eds.): *Diet and health in past animal populations: Current research and future directions*: 52-57. Oxbow Books, Oxford.
- HASELGROVE, C. 1999: The Iron Age. In: Hunter, J.R. & Ralston, I.B.M. (eds.): *The Archaeology of Britain: an introduction from the Upper Palaeolithic to the Industrial Revolution*: 113-134. Routledge, London.
- LEVINE, M.A. 2005: Origins and selection of horse behaviour. In: Mills, D. & McDonnell, S. (eds.): *The Domestic Horse: the Origins, Development and Management of its Behaviour*: 5-22. Cambridge University Press, Cambridge.
- LEVINE, M.A. 2004: Exploring the Criteria for Early Horse Domestication. In: Jones, M. (ed.): *Traces of ancestry: studies in honour of Colin Renfrew*: 115-126. McDonald Institute for Archaeological Research, Cambridge.
- LEVINE, M.A.; BAILEY, G.N.; WHITWELL, K.E. & JEFFCOTT, L.B. 2000: Palaeopathology and Horse Domestication: the case of some Iron Age horses from the Altai Mountains, Siberia. In: Bailey, G.; Charles, R. & Winder, N. (eds.): *Human Ecodynamics and Environmental Archaeology*: 123-33. Oxbow, Oxford.
- LEVINE, M.A.; WHITWELL, K.E. & JEFFCOTT, L.B. 2002: A Romano-British horse burial from Icklingham, Suffolk. *Archaeofauna* 11: 63-102.
- OLSEN, S.L. 2006: Early Horse Domestication on the Eurasian Steppe. In: Zeder, M.A.; Bradley, D.G.; Emshwiller, E. & Smith, B.D. (eds.): *Documenting Domestication: New Genetic and Archaeological Paradigms*: 245-269. University of California Press, Berkeley.
- OLSEN, S.L. 2003: The exploitation of horses at Botai, Kazakhstan. In: Levine, M.; Renfrew, C. & Boyle, K. (eds.): *Prehistoric steppe adaptation and the horse*: 83-103. McDonald Institute for Archaeological Research, Cambridge.
- RACKHAM, D.J. 1995: Appendix: skeletal evidence of medieval horses from London sites. In: Clark, J.: *The Medieval Horse and its Equipment*: 169-74. HMSO, London.
- ROONEY, J.R. 1997: Equid Palaeopathology. *Journal of Equine Veterinary Science* 17: 430-446.

- SISSON, S. & GROSSMAN, J.D. 1966: *The Anatomy of Domestic Animals*. W.B. Saunders Company, London. Fourth edition.
- STECHEER, R.M. & GOSS, L.J. 1961: Ankylosing Lesions of the Spine. *Journal of the American Veterinary Medical Association* 138(5): 248-255.
- SULLINS, K.E. 2002: The tarsus. In: Stashak, T.S. (ed.): *Adams' lameness in horses*: 930-987. Lippincott Williams & Williams, Philadelphia. Fifth edition.
- YATES, D. 2001: Bronze Age agricultural intensification in the Thames Valley and Estuary. In: Brück, J. (ed.): *Bronze Age Landscapes: Tradition and Transformation*: 65-82. Oxbow Books, Oxford.